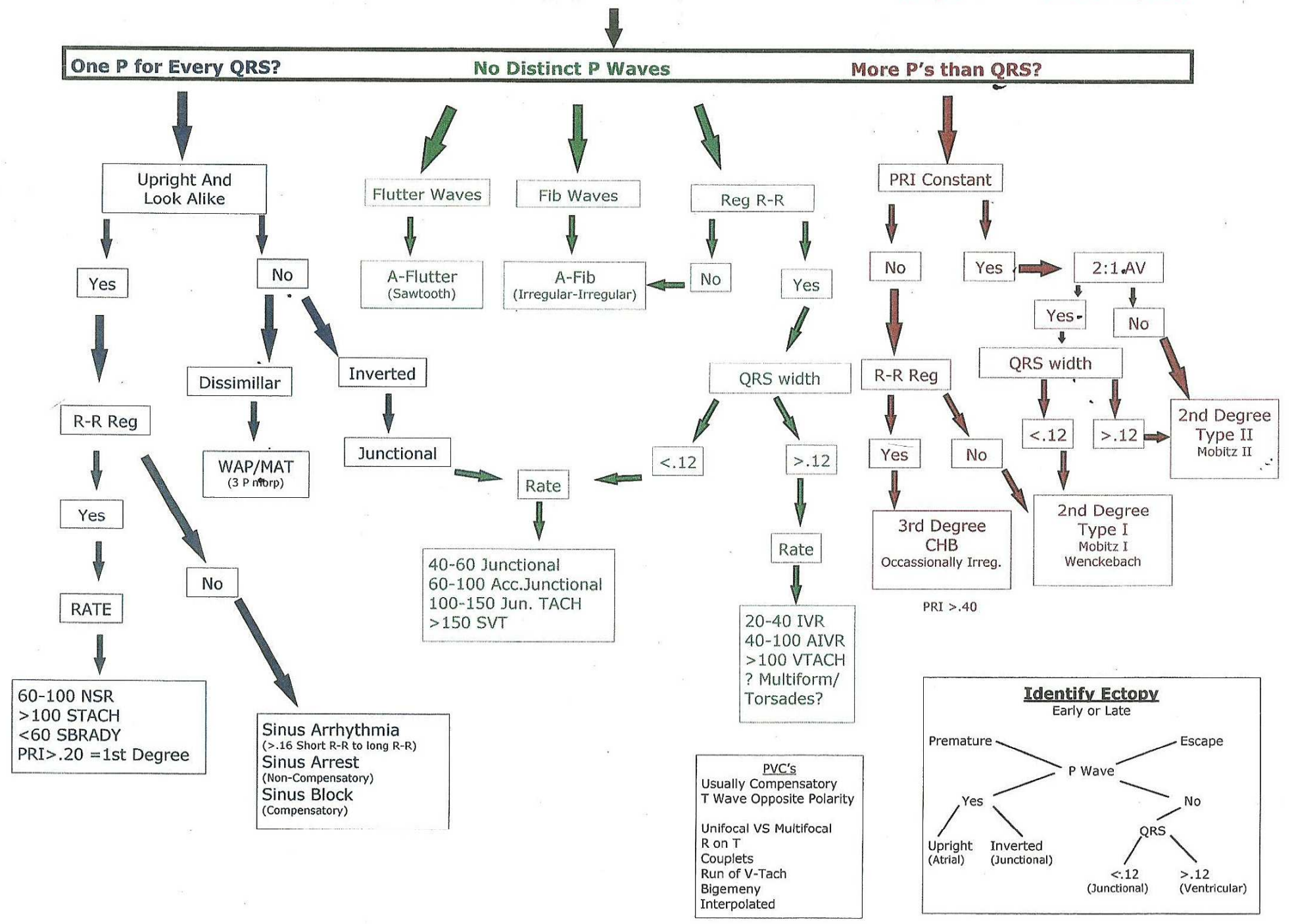


Robert Z...

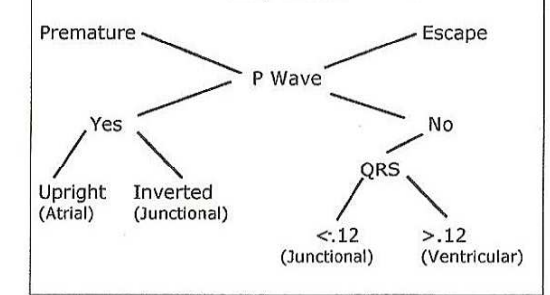
Rhythm Interpretation Flow Chart

Check underlying rate & rhythm -----> No QRS = V-Fib or Asystole



Identify Ectopy

Early or Late



PVC's
Usually Compensatory
T Wave Opposite Polarity

Unifocal VS Multifocal
R on T
Couplets
Run of V-Tach
Bigeminy
Interpolated